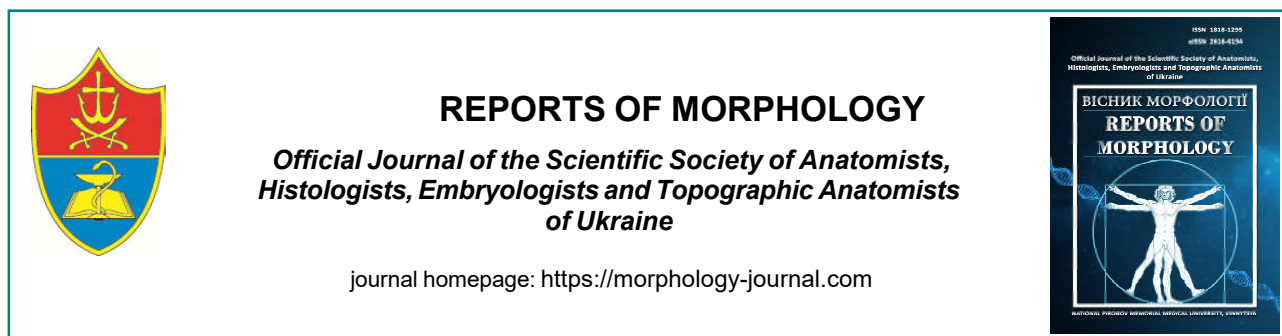



REPORTS OF MORPHOLOGY

Official Journal of the Scientific Society of Anatomists,
Histologists, Embryologists and Topographic Anatomists
of Ukraine

journal homepage: <https://morphology-journal.com>

The results of morphological studies in women of reproductive age with hyperproliferative diseases of the endometrium

Abdullaiev V. E.

National Pirogov Memorial Medical University, Vinnytsya, Ukraine

ARTICLE INFO

Received: 29 November 2021

Accepted: 11 January 2022

UDC: 618.14-002.2-007.61

CORRESPONDING AUTHOR

e-mail: vahif.abdullaiev@gmail.com
Abdullaiev V. E.

CONFLICT OF INTEREST

The authors have no conflicts of interest to declare.

FUNDING

Not applicable.

Hyperproliferative processes of the endometrium, remaining one of the most common gynecological pathologies, still have imperfections in the diagnostic stages, both invasive and non-invasive. There is still controversy about the need to differentiate between hyperplasia and endometrial polyps. And the improvement of the method of pathomorphological research and the invention of immunohistochemical markers for the endometrium, opened new opportunities for better diagnosis of hyperproliferative processes of the endometrium. Also, an important component of the diagnosis of endometrial pathology are invasive methods, namely hysteroscopy, which has eliminated most of the shortcomings associated with the classic scraping of the uterine cavity. The definition of markers of chronic endometritis has opened new questions about the origin of chronic inflammation in the uterine cavity, its course and the relationship with the biocenosis of the lower genital tract. The aim of this study was to determine the role of pathomorphological immunohistochemical cytological methods of examination and microscopy in patients of reproductive age with hyperproliferative processes of the endometrium. In order to achieve this goal, we analyzed 161 women, of whom 58 women had verified diagnoses of endometrial hyperproliferative processes, 71 women were morphologically verified diagnoses of hyperproliferative processes in combination with chronic endometritis. The control group consisted of 32 women without evidence of hyperproliferative processes of the endometrium and chronic endometritis. The age of women ranged from 18 to 53 years. Also, all women underwent cytological examination of the cervix and microscopy of vaginal swabs. According to the data obtained, the percentage ratio between the number of diagnosed endometrial polyps and endometrial hyperplasia was equal, with a slight advantage towards endometrial polyps. Other gynecological diseases such as uterine fibroids, external endometriosis and cervical polyps accounted for a total of 0.8 to 3.9%. Cytological examination of the cervix indicated the predominance of type 2 cytology in the group of women with chronic endometritis. Analysis of microscopic data of vaginal secretions indicates an increased level of inflammation in the group of women with a combination of hyperplastic processes of the endometrium and chronic endometritis. In conclusion, it is possible to claim a slightly higher level of chronic endometritis in the group of women with endometrial polyps, compared with endometrial hyperplasia. There is also a clear link between the diagnosis of chronic endometritis and inflammatory changes in cytological examination of the cervix and microscopy of vaginal discharge. Comparison of the results of the above diagnostic methods can improve the diagnosis of hyperproliferative processes of the endometrium and chronic endometritis, with the further development of effective treatment methods.

Keywords: endometrial hyperplasia, endometrial polyps, endometrial hyperproliferative processes, pathomorphological study, immunohistochemical study, cytological examination.

Introduction

Hyperproliferative diseases of the endometrium (HE) attract the attention of scientists and practitioners because they have a high risk of progression to neoproliferative

processes [1, 2]. At the same time, there are many differences in the interpretation of the etiopathogenetic aspects of these processes, their classification and

methods of treatment. The issue of endometrial polyps (PE) is debatable, most authors consider them a special form of proliferative process, and distinguish it from endometrial hyperplasia [2, 3, 5]. At the same time, some authors believe that endometrial polyps are a local form of endometrial hyperplasia, and polyps larger than 15 mm in diameter are generally considered a manifestation of diffuse endometrial hyperplasia [7, 10]. The WHO has adopted a classification of proliferative processes - hyperplasia in two forms: without atypia and with atypia. Despite the large amount of research on various aspects of endometrial hyperplastic processes, the role of inflammatory processes in the pathogenesis of endometrial hyperplasia and polyps remains controversial, the possibility of using anti-inflammatory therapy in conservative treatment of hyperplastic processes and prevention of malignancy is unclear [10, 12].

In addition to the study of anamnesis, the use of laboratory and non-invasive methods of endometrial examination, invasive diagnostic techniques with subsequent morphological examination have become widely used [11, 15]. According to endometrial biopsy, we have the opportunity to obtain sufficiently informative material for diagnosis, while some authors point to its lack of information due to possible technical errors, such as the inability to remove polyps in this way. However, the combination of this method with hysteroscopy allows for better diagnosis of hyperproliferative processes of the endometrium [13, 18, 21].

Hysteroscopy is now considered the most reliable method for diagnosing hyperproliferative processes of the endometrium, and the doctor has the opportunity not only to assess visually pathological changes, but also to conduct targeted surgery, to assess its effectiveness. The informativeness of hysteroscopy is estimated by various authors in 84-96 % [16, 17]. Some authors point out the disadvantages of this method, the presence of individual errors caused by the peculiarities of changes in the endometrium.

Finally, the diagnosis of hyperproliferative processes of the endometrium can be established as a result of histological examination of the surgical material [19]. Histological examination makes it possible to assess not only the form of hyperproliferative processes of the endometrium, but also the presence of signs of neoproliferative process in the studied material. The main question to be answered by histological diagnosis is the presence or absence of signs of atypia.

Different authors determine the different effectiveness of hysteroscopy in chronic endometritis (CE), and differences in estimates are quite polar: from 16 to 93 % of cases [19, 20]. At the same time, the presence of such signs as uneven endometrial thickness, focal hypertrophy of the mucous membrane, the presence of polypoid growths, hyperemia or uneven coloration of the mucous membrane suggest the presence of chronic endometritis [20].

Immunohistochemical method detects markers characteristic of chronic endometritis: CD68+, CD45+, CD56+, CD20+, CD16+, rarely CD4+, CD8+. For autoimmune chronic endometritis is characterized by an increase in CD56+ in the amount of 25-60 in the field of view. Most authors point out that the most important sign of chronic endometritis is the presence of markers of plasma CD138+ cells in lymphoid infiltrates of the endometrial stroma [19, 20, 21].

The final point in the diagnosis of chronic endometritis makes it possible to put a morphological examination of the endometrium. In the presence of inflammatory infiltrates in the endometrium, which consist mainly of lymphoid elements located around the glands and blood vessels; especially in the presence of plasma cells in these infiltrates, the presence of fibrosis of the endometrial stroma and sclerotic changes in the walls of the spiral arteries of the uterus, we have the opportunity to diagnose chronic endometritis.

The aim of the study is to compare the results of pathomorphological and immunohistochemical methods of endometrial examination with methods of diagnosing the biocenosis of the lower parts of the female genital tract.

Materials and methods

According to the conclusion of the **Committee on Bioethics** of the National Pirogov Memorial Medical University, Vinnytsya № 2 dated 10.02.2022, the research methods described in the publication were applied in compliance with human rights in accordance with current legislation in Ukraine, meet international ethical requirements and do not violate ethical norms and standards. conducting biomedical research.

In connection with the objectives of the study analyzed the results of laboratory studies of 161 women, of whom 58 had verified diagnoses of endometrial hyperplastic processes (group 1), and 71 were found morphologically verified hyperplastic processes in combination with chronic endometritis registered in 2018 until 2020 (group 2). The control group consisted of 32 women without signs of hyperplastic processes and chronic endometritis.

In verifying the diagnosis used common morphological signs of chronic endometritis [6]:

- the presence in the endometrium of inflammatory infiltrates, which consist mainly of lymphoid elements with the inclusion of macrophages and eosinophils and are located more often around the glands and blood vessels, rarely diffuse;
- the presence of plasma cells in infiltrates;
- focal stroma fibrosis;
- sclerotic changes in the walls of the spiral arteries of the endometrium.

In all cases, the so-called "complete symptom complex of chronic endometritis" was verified, ie the presence of not one but all morphological signs of the disease from the above list.

Vaginal smear microscopy and determination of the degree of purity of secretions were used to assess the state of the biocenosis of the lower genital tract of the examined women.

For the purpose of early diagnosis of oncological diseases and determination of the condition of the cervical epithelium, we performed a cytological examination of the cervix in women.

Statistical data processing was performed on a personal computer using Microsoft Excel spreadsheets and the application package Statistica for Windows V.7.0, StatSoft Inc. (USA). All obtained quantitative data were processed by the method of variation statistics. Percentages were determined for each relative parameter. For nonparametric data, the ϕ -Fisher angular transformation method was used (for 2 groups) for unrelated sets.

Results

After careful collection of anamnestic data, detection of clinical manifestations, gynecological examination, performed pathomorphological and immunohistochemical examination of endometrial samples. Pathomorphological examination of the endometrium to verify the diagnosis of chronic endometritis and hyperplastic processes of the endometrium was performed in all patients. The results of the morphological study are presented in table 1.

According to our data, in patients of the studied groups in 44.2 % of cases there was endometrial hyperplasia without atypia, in 55.8 % local endometrial hyperplasia (polyp), in 55.0 % of women signs of chronic endometritis, in 55.8 % - CD138 expression, in addition to isolated fibroids cases (1.6 %), endometrioid cyst (3.1 %), endometrial rejection disorders (3.9 %), cervical polyps (0.8 %).

The results of cytological examination of the cervix are presented in table 2 and figure 1.

According to the results of our study, the 2nd grade of

Table 1. The results of morphological examination in patients of the studied groups.

Nosology	Group 1 (n=58)		Group 2 (n=71)		Fisher's ratio ϕ	Total (n=129)	
	n	%	n	%		n	%
Endometrial hyperplasia without atypia	26	44.8	31	43.7	0.125	57	44.2
Endometrial polyp	32	55.2	40	56.3	0.124	72	55.8
Chronic endometritis	0	0	71	100	17.75**	71	55.0
Progesterone receptor expression	1	1.7	1	1.4	0.137	2	1.6
Expression of CD138	1	1.7	71	100	16.27**	72	55.8
Fibroids	1	1.7	1	1.4	0.137	2	1.6
Endometrioid cyst	0	0	4	5.6	2.700**	4	3.1
Disorders of endometrial rejection	1	1.7	4	5.6	1.222	5	3.9
Cervical polyp	0	0	1	1.4	1.340	1	0.8

Notes: * - $p < 0.05$; ** - $p < 0.01$.

Table 2. The results of cytological examination of the cervix in patients of the studied groups.

Nosology	Group 1 (n=58)		Group 2 (n=71)		Fisher's ratio ϕ	Total (n=129)	
	n	%	n	%		n	%
Grade 1	9	15.5	6	8.5	1.229	15	11.6
Grade 2	37	63.8	58	81.7	2.300*	95	73.6
Grade 3	12	20.7	7	9.9	1.720	19	14.8

Notes: * - $p < 0.05$; ** - $p < 0.01$.

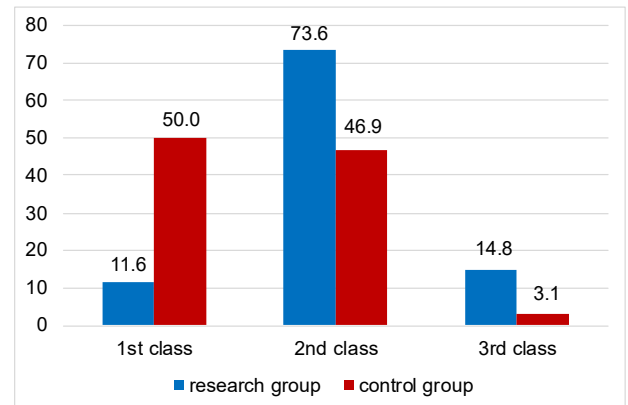


Fig. 1. Comparative diagrams of the results of cytological examination of the cervix in women from control and study groups.

cervical cytology prevailed in both study groups (63.8 % in the group of women with hyperplastic endometrial processes, and 81.7 % in the group of women with a combination of endometrial hyperplastic processes and chronic endometritis, $p < 0.05$). For other grades (1st and 3rd) we did not find statistically significant differences for the indicators of the studied groups.

In the studied groups, the highest rate was set for grade 2 cytology of the cervix, which indicates the presence of elements of inflammation. This parameter was statistically significantly higher than the same indicator of the control group (73.6 % vs. 46.9 %, respectively, $p < 0.05$). It should be noted that in the control group the highest was the indicator of the 1st grade of cytology (corresponding to the norm), which was significantly higher than the studied groups of women with pathology (50.0 % vs. 11.6 %, respectively, $p < 0.01$). The significant advantage of the 3rd grade of cytology (focal changes without atypia) in the studied women (14.8 % vs. 3.1 % in the control group, $p < 0.05$) is noteworthy.

We note a tendency for a slightly higher rate of cytology grade 2 in women with chronic endometritis, compared with endometrial hyperplastic processes (71.9 vs. 53.8 %, respectively) and the predominance of cytology grade 3 in women with HE over PE (34.8 vs. 12.5 %, respectively), but they are not statistically significant ($p > 0.05$).

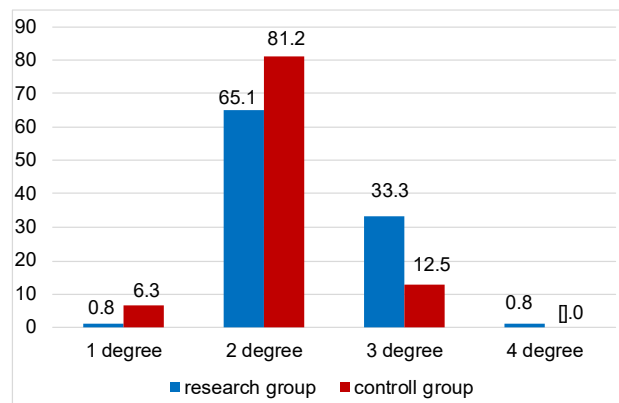
The results of determining the degree of purity of secretions in women of the study groups are presented in table 3.

In women of the studied groups there is a predominance of 2 degrees of purity (65.1 %), less (33.3 %) - 3 degrees of

Table 3. The degree of purity of secretions in women of the study groups.

Nosology	Group 1 (n=58)		Group 2 (n=71)		Fisher's ratio φ	Total (n=129)	
	n	%	n	%		n	%
1 degree	0	0	1	1.4	1.340	1	0.8
2 degree	47	81.0	37	52.1	3.541**	84	65.1
3 degree	11	19.0	32	45.1	3.224**	43	33.3
4 degree	0	0	1	1.4	1.340	1	0.8

Notes: * - $p < 0.05$; ** - $p < 0.01$.

**Fig. 2.** Comparative diagrams of the microscopy results of vaginal swabs in women from control and study groups.

purity, with a small amount (0.8 %) of 1 degree and 4 degrees of purity (Fig. 2).

Comparing the data of studies of discharges between patients in the study groups, our attention was drawn to the fact that the group of women with HE significantly dominated by smears of 2 degrees of purity with leukocytes up to 10, a large number of lactobacilli, moderate microflora (81.0 % vs. 52.1 % in women with HE and CE, $p < 0.01$). Also in this group the indicator of 3 degrees of purity of smears was significantly lower (19.0 % against 45.1 %, respectively, $p < 0.01$). Thus, in the 2nd group smears with the number of leukocytes 10-30, a small number of lactobacilli, moderate mixed microflora predominates. Thus, the group of women with HE is dominated by smears typical of healthy women who are already having sex, and in the group of women with a combination of HE and CE a high percentage of respondents at high risk of developing inflammatory diseases (vulvovaginitis, etc.).

According to our data, the control group is dominated by women with normal microflora (1 and 2 degrees of purity) - 87.5 % against 65.9 % of women in the study groups ($p < 0.05$). Among women in the study groups, in particular, respondents with a combination of HE and CE, indicators with a high risk of infectious diseases (3-4 degrees of purity) prevail - 34.1 % vs. 12.5 %, respectively.

Discussion

The distribution of the structure of endometrial hyperproliferative processes into polyps and endometrial

hyperplasia, according to our data, is uniform, with a slight advantage towards endometrial polyps, which is consistent with the authors Chen Y. Q. and co-authors [3] and Fang R. L. and co-authors [8]. In addition, according to Cicinelli E. co-authors [5] and Cheung W. and Cheung V. [4], the presence of patients with a confirmed diagnosis of endometrial hyperproliferative processes does not exclude the presence of concomitant gynecological diseases such as uterine fibroids, external endometriosis and cervical polyps. The presence of pathomorphologically confirmed diagnosis of hyperproliferative processes of the endometrium significantly increases the risk of a positive immunohistochemical marker of chronic endometritis, especially in the group of endometrial polyps [4, 5].

In turn, chronic endometritis, as a possible risk factor for hyperproliferative processes of the endometrium requires both immunohistochemical verification and pathomorphological confirmation using multiple criteria, such as the presence of plasma cells, inflammatory infiltration, stroma fibrosis, sclerotic changes [7, 9, 11]. It should be noted that patients with hyperproliferative processes of the endometrium and chronic endometritis with a higher frequency have type 2 cytological examination of the cervix with inflammation and increased inflammation according to microscopy of vaginal discharge [11, 14]. According to Clark T.J. and Stevenson H. [6], endometrial polyps increase the risk of developing chronic endometritis compared to other types of endometrial hyperproliferative processes, which is comparable to the results of our study. It is an indisputable fact that chronic endometritis may be the basis for the development of hyperproliferative processes of the endometrium, which may under certain conditions progress to atypical endometrial hyperplasia and endometrial adenocarcinoma.

The attention of scientists is also drawn to the interaction of the infectious agent with the protective systems of the female body. Thus, the presence of a large number of lactobacilli is considered an indicator of normal microflora, which counteracts the development of other groups of potentially dangerous microorganisms. Thus, Fang R. L. and co-authors [8] indicated a fairly high level of lactobacilli in patients with endometrial polyps (38.6 %). The data of these authors are slightly lower than ours, but it should be borne in mind that in this study we took into account only the degree of bacterial purity. At the same time, these data are refined by Kimura F. and co-authors [13], who indicate that the study on CD138 did not reveal statistically significant differences between women with and without chronic endometritis. According to researchers, this suggests that the interaction between the infectious agent and endometrial immunity is important in the development of chronic inflammation.

Another topical issue that is widely studied in the context of endometrial hyperproliferative processes associated with chronic endometritis is the problem of fertilization of the ovum and pregnancy, which makes the problem of

combining hyperproliferative processes of the endometrium and chronic endometritis multidisciplinary, relevant for obstetricians and gynecologists, as well as for oncogynecologists and reproductive specialists [9, 21]. Today, there are a small number of published studies that describe the relationship between chronic endometritis and the microflora of the lower female genitalia. Studying such relationships may be key to discovering the pathogenesis of chronic endometritis. Authors Cheung W. and Cheung V. [4] compared the origins of chronic inflammatory processes of the fallopian tubes and uterine cavity, which in our opinion is a very promising area. An important aspect in studying the origin of chronic endometritis is the use of modern diagnostic techniques. In our opinion, the combination of classical diagnostic techniques such as microscopy and cytology with modern immunohistochemical markers is optimal, which may be the optimal solution to the treatment of chronic endometritis [16, 18].

The above diagnostic techniques do not allow to decide on the appointment of etiopathogenetic treatment, but only to state the fact of diagnosis of chronic endometritis. In this case, it may be useful to use PCR to determine the pathogen and bacterial load in the test material. At this stage, before the invention and widespread implementation

of unified diagnostic and therapeutic approaches to the treatment of chronic endometritis, diagnosis requires an extended approach using many different techniques and comparing their results [3, 5, 9, 15].

Conclusions

1. Patients with endometrial polyps have a higher risk of developing chronic endometritis compared with patients with endometrial hyperplasia.

2. To detect chronic endometritis as a cause of hyperproliferative processes of the endometrium, it is advisable to use a combined diagnostic approach using pathomorphological examination with many criteria, immunohistochemical marker CD138, cytological examination of the cervix and microscopy of vaginal secretions.

3. The obtained results confirm the common origin of chronic inflammation of different parts of the female genital tract and indicate its connection with the occurrence of hyperproliferative processes of the endometrium.

4. PCR diagnosis of endometrial samples can be considered a promising area for the diagnosis of etiological factors of chronic endometritis in patients with hyperproliferative processes of the endometrium.

References

- [1] Akeda, K., An, H. S., Okuma, M., Attawia, M., Miyamoto, K., Thonar, E. J.-M. A., ... Masuda, K. (2016). Platelet-rich plasma stimulates porcine articular chondrocyte proliferation and matrix biosynthesis. *Osteoarthritis Cartilage*, 14(12), 1272-1280. doi: 10.1016/j.joca.2006.05.008
- [2] Benyuk, V. O., Goncharenko, V. M., Zabudskiy, O. V., & Yarmak, V. S. (2015). Роль хронічного ендометриту в генезі гіперпластичних процесів ендометрію [The role of chronic endometritis in the genesis of hyperplastic endometrial processes]. *Здоров'я жінки - Woman's Health*, 102(6), 16-21.
- [3] Chen, Y. Q., Fang, R. L., Luo, Y. N., & Luo, C. Q. (2016). Analysis of the diagnostic value of CD138 for chronic endometritis, the risk factors for the pathogenesis of chronic endometritis and the effect of chronic endometritis on pregnancy: a cohort study. *BMC Womens Health*, 16(1), 60. doi: 10.1186/s12905-016-0341-3
- [4] Cheung, W., & Cheung, V. (2017). Coexisting Endosalpingiosis and Subserous Adenomyosis. *J. Min. Invasive Gyn.*, (22), 315-316. doi: 10.1016/j.jmig.2014.07.012
- [5] Cicinelli, E., Matteo, M., Tinelli, R., Lepera, A., Alfonso, R., Indraccolo, U., ... Resta, L. (2015). Prevalence of chronic endometritis in repeated unexplained implantation failure and the IVF success rate after antibiotic therapy. *Hum. Reprod. Oxf. Engl.*, 30(2), 323-330. doi: 10.1093/humrep/deu292
- [6] Clark, T. J., & Stevenson, H. (2017). Endometrial Polyps and Abnormal Uterine Bleeding (AUB-P): What is the relationship, how are they diagnosed and how are they treated? *Best Pract. Res. Clin. Obstet. Gynaecol.*, (40), 89-104. doi: 10.1016/j.bpobgyn.2016.09.005
- [7] Committee on Gynecologic Practice, Society of Gynecologic Oncology. (2015). Committee on Gynecologic Practice, Society of Gynecologic Oncology Committee opinion № 631. Endometrial intraepithelial neoplasia. *Obstetrics & Gynecology*, 125(5), 1272-1278. doi: 10.1097/01.AOG.0000465189.50026.20
- [8] Fang, R. L., Chen, L. X., Shu, W. S., Yao, S. Z., Wang, S. W., & Chen, Y. Q. (2016). Barcoded sequencing reveals diverse intrauterine microbiomes in patients suffering with endometrial polyps. *American Journal of Translational Research*, 8(3), 1581-1592.
- [9] Gombolevska, N. A., & Marchenko, L. A. (2012). Современные критерии диагностики хронического эндометрита (обзор литературы) [Modern criteria for the diagnosis of chronic endometritis (literature review)]. *Проблемы репродукции - Reproduction Problems*, 18(1), 42-46.
- [10] Horban, N. Y., Vovk, I. B., Lysiana, T. O., Ponomariova, I. H., & Zhulkevych, I. V. (2019). Peculiarities of uterine cavity biocenosis in patients with different types of endometrial hyperproliferative pathology. *Journal of Medicine and Life*, 12(3), 266-270. doi: 10.25122/jml-2019-0074
- [11] Huchon, C., Koskas, M., Agostini, A., Akladios, C., Alouini, S., Bauville, E., ... Fauconnier, A. (2015). Operative hysteroscopy versus vacuum aspiration for incomplete spontaneous abortion (HY-PER): study protocol for a randomized controlled trial. *Trials*, 16, 363. doi: 10.1186/s13063-015-0900-1
- [12] Khmil, S. V., Khmil, M. S., Drozdovska, Yu. B., & Chudiiiovych, N. Ya. (2018). Ефективність гістероскопії у жінок з безпліддям на фоні лейоміоми матки в програмах допоміжних репродуктивних технологій [Efficiency of hysteroresctoscopy in women with infertility in the background of uterine leiomyomas in the programs of assisted reproductive technologies]. *Вісник соціальної гігієни та організації охорони здоров'я України - Bulletin of Social Hygiene and Health Protection Organization of Ukraine*, 78(4), 51-55. doi: 10.11603/1681-2786.2018.4
- [13] Kimura, F., Takebayashi, A., Ishida, M., Nakamura, A., Kitazawa, J., ... Murakami, T. (2019). Review: Chronic endometritis and

- its effect on reproduction. *J. Obstet. Gynaecol. Res.*, 45(5), 951-960. doi: 10.1111/jog.13937
- [14] Kitaya, K., Tada, Y., Hayashi, T., Taguchi, S., Funabiki, M., & Nakamura, Y. (2014). Comprehensive endometrial immunoglobulin subclass analysis in infertile women suffering from repeated implantation failure with or without chronic endometritis. *Am. J. Reprod. Immunol.*, 72(4), 386-391. doi: 10.1111/aji.12277
- [15] Kitaya, K., Yasuo, T., Tada, Y., Hayashi, T., Iwaki, Y., Karita, M., ... Yamada, H. (2014). Unusual inflammation in gynecologic pathology associated with defective endometrial receptivity. *Histol. Histopathol.*, 29(9), 1113-1127. doi: 10.14670/hh-29.1113
- [16] Moreno, I., Cicinelli, E., Garcia-Grau, I., Gonzalez-Monfort, M., Bau, D., Vilella, F., ... Simon, C. (2018). The diagnosis of chronic endometritis in infertile asymptomatic women: a comparative study of histology, microbial cultures, hysteroscopy, and molecular microbiology. *AJOG*, 218(6), 602. doi: 10.1016/j.ajog.2018.02.012
- [17] Nijkang, N. P., Anderson, L., Markham, R., & Manconi, F. (2019). Endometrial polyps: Pathogenesis, sequelae and treatment. *SAGE Open Med.*, 7, 1-12. doi: 10.1177/2050312119848247
- [18] Puente, E., Alonso, L., Lagana, A. S., Ghezzi, F., Casarin, J., & Carugno, J. (2020). Chronic endometritis: Old problem, novel insights and future challenges. *Int. J. Fertil. Steril.*, 13(4), 250-256. doi: 10.22074/ijfs.2020.5779
- [19] Resta, L., Palumbo, M., Piscitelli, D., Grazia Fiore, M., & Cicinelli, E. (2012). Histology of micro polyps in chronic endometritis. *Histopathology*, 60(4), 670-674. doi: 10.1111/j.1365-2559.2011.04099.x
- [20] Sfakianoudis, K., Simopoulou, M., Nitsos, N., Lazaros, L., Rapani, A., Pantou, A., ... Pantos, K. (2019). Successful Implantation and Live Birth Following Autologous Platelet-rich Plasma Treatment for a Patient with Recurrent Implantation Failure and Chronic Endometritis. *In Vivo*, 33(2), 515-521. doi: 10.21873/invivo.11504
- [21] Vaskkivuo, T., Stenback, F., & Tapanainen, J. (2012). Apoptosis and apoptosis-related factors Bcl-2, Bax, tumor necrosis factor-alpha, and NFkappaB in human endometrial hyperplasia and carcinoma. *Cancer*, 95(7), 1463-1471. doi: 10.1002/cncr.10876
- [22] Wu, D., Kimura, F., Zheng, L., Ishida, M., Niwa, Y., Hirata K., ... Murakami, T. (2017). Chronic endometritis modifies decidualization in human endometrial stromal cells. *Reprod. Biol. Endocrinol.*, 15(1), 16. doi: 10.1186/s12958-017-0233-x

РЕЗУЛЬТАТИ МОРФОЛОГІЧНОГО ДОСЛІДЖЕННЯ У ЖІНОК РЕПРОДУКТИВНОГО ВІКУ З ГІПЕРПРОЛІФЕРАТИВНИМИ ЗАХВОРЮВАННЯМИ ЕНДОМЕТРІЯ

Абдуллаєв В. Е.

Гіперпроліферативні процеси ендометрія, залишаючись однією з найбільш розповсюджених гінекологічних патологій, усе ще мають недосконалість на етапах діагностики як інвазивної, так і неінвазивної. Досі існують суперечності у необхідності диференціації між гіперплазією та поліпами ендометрія. Удосконалення методики патоморфологічного дослідження та винайдення імуногістохімічних маркерів для ендометрія відкрило нові можливості для більш досконалої діагностики його гіперпроліферативних процесів. Важливою складовою діагностики патології ендометрія є гістероскопія, котра дозволила усунути більшість недоліків, пов'язаних із класичним вишкрібанням порожнини матки. Визначення маркерів хронічного ендометриу відкрило нові запитання про походження хронічного запального процесу в порожнині матки, його перебіг та взаємозв'язок з біоценозом нижчих відділів статевого тракту. Метою даного дослідження стало порівняння результатів патоморфологічного та імуногістохімічного дослідження ендометрія з методами діагностики біоценозу нижніх відділів жіночого статевого тракту. З метою виконання встановленої мети нами було проведено аналіз результатів лабораторних досліджень у 161 жінки, з яких 58 жінок мали верифіковані діагнози гіперпроліферативних процесів ендометрія, 71 жінці було встановлено морфологічно верифіковані діагнози гіперпроліферативних процесів у поєднанні з хронічним ендометритом. Контрольну групу становили 32 жінки без ознак гіперпроліферативних процесів ендометрія та хронічного ендометриу. Вік жінок становив від 18 до 53 років. Усім жінкам було проведено цитологічне дослідження шийки матки та мікроскопія вагінальних мазків. За отриманими даними відсоткове співвідношення між кількістю діагностованих поліпів ендометрія та гіперплазії ендометрія виявилось однаковим із незначною перевагою кількості поліпів. Інші гінекологічні захворювання (міома матки, зовнішній ендометріоз та поліпи шийки матки) становили від 0,8 до 3,9 %. Цитологічне дослідження шийки матки вказало на перевагу 2 типу цитології у групі жінок з хронічним ендометритом. Аналіз даних мікроскопії вагінальних виділень вказує на підвищений рівень запальних показників у групі жінок з поєднанням гіперпластичних процесів ендометриу та хронічного ендометриу. Таким чином, можливо стверджувати про незначно вищий рівень хронічного ендометриу у групі жінок з поліпами ендометрія порівняно з гіперплазією ендометрія. Встановлено прямий взаємозв'язок між діагностикою хронічного ендометриу та запальними змінами у цитологічному дослідженні шийки матки з мікроскопією вагінальних виділень. Порівняння результатів вище перелічених діагностичних методів дозволяє покращити діагностику гіперпроліферативних процесів ендометрія та хронічного ендометриу.

Ключові слова: гіперплазія ендометрія, поліпи ендометрія, гіперпроліферативні процеси ендометрія, патоморфологічне дослідження, імуногістохімічне дослідження, цитологічне дослідження.